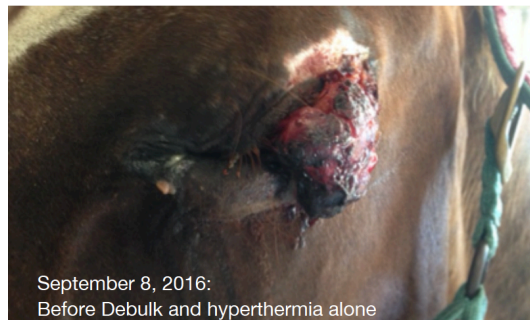



Making Strides with Sarcoid Treatment

By Dr. Alex Urban

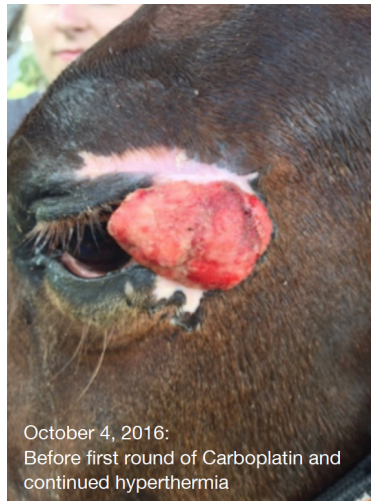
Sarcoids are locally aggressive, non-malignant tumors of the equine skin. In fact, these tumors are the most common skin neoplasm in horses. Their cause is still unknown, though research indicates involvement of bovine papilloma virus spread by biting flies. Of the six types that exist (flat, verrucous, nodular, fibroblastic, mixed, and malevolent), benign neglect is often the medical choice as trauma may incite proliferation of the mass. In the case of aggressive fibroblastic sarcoids or nodular lesions that are interfering with normal locomotion, urination/defecation, or are being traumatized due to location, treatment may be pursued. A variety of therapies exist including topical application of herbal and pharmaceutical preparations, surgical excision/debulking, carbon dioxide laser, and cryosurgery (freezing of the site with liquid nitrogen). Chemotherapy (such as cisplatin, carboplatin, and 5-fluorouracil) can also be implanted, injected, or applied topically. Of these treatments, none has shown to be particularly more successful than the others, and no single therapy is effective in all cases. A new modality has made its way into the world of equine oncology (cancer/tumor therapy) called hyperthermia; it has been used in human medicine, as well as small animal medicine, for some time. Hyperthermia is deeply focused heat applied to the lesion, with effectiveness up to 10 cm depth and greatest temperature at 3-5 cm tissue depth. The heat causes direct damage to the tumor cells, as well as production of heat shock proteins that increase the immune system's ability to detect and attack abnormal cells. In addition, the heat encourages blood flow and oxygen delivery to the tumor, which allows better uptake of any chemotherapy agent into the cancer cells. It is this combination treatment of chemotherapy and hyperthermia that has shown promising results in the treatment of aggressive sarcoids, both at the university setting and in private practice.

Brandon Equine Medical Center has been treating a particularly aggressive fibroblastic sarcoid for approximately a year and a half, with optimistic results achieved only recently using multimodal therapy. The 17 YO quarter horse mare was first seen back in September 2015 after a fibroblastic sarcoid on the outside corner of her left eye had been treated elsewhere with 5-FU, Xxterra, Carboplatin injection, and debulking. At that time, it was again debulked, then several Cisplatin beads placed intratumorally as chemotherapy. Over the next year, the sarcoid continued to recur after various treatments including further debulking, cisplatin beads, cryotherapy, Chinese herbs, and Aldara cream.

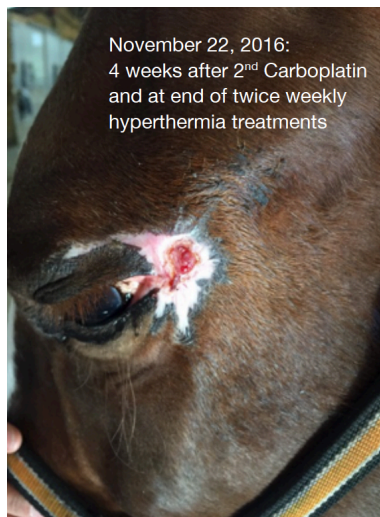

September 8, 2016:
Before Debulk and hyperthermia alone

In September 2016, hyperthermia treatment as a solo therapy was initiated. Though it slowed the growth of the tumor and decreased angry nature of the lesion, the sarcoid continued to recur and obscure proper lid closure.



Debulking was performed and Carboplatin injected into the tumor at the beginning of October, followed by twice weekly hyperthermia sessions for 4 weeks. The lesion improved immensely, but still had a small amount of regrowth. A second round of Carboplatin was injected followed by twice weekly hyperthermia. At the time of publication, the treatment site is healing well with no sign of regrowth.



We hope that this new modality – hyperthermia—combined with mass removal and chemotherapy as above will give similar results in other sarcoid cases. In addition, this protocol has shown promising results for squamous cell carcinoma.

Contact Brandon Equine Medical Center at 813-643-7177 or email info@brandonequine.com with any questions regarding this topic.

For more articles on horse health topics visit our website <http://brandonequine.com/publications.php>

This article originally appeared in Horse & Pony magazine in January, 2017 and is reprinted with their permission.